

Laerdal SonoSim Ultrasound Solution (LSUS) 2.0 SimMom Late-Stage Pregnancy Healthy Patient Peer-to-Peer Checklist

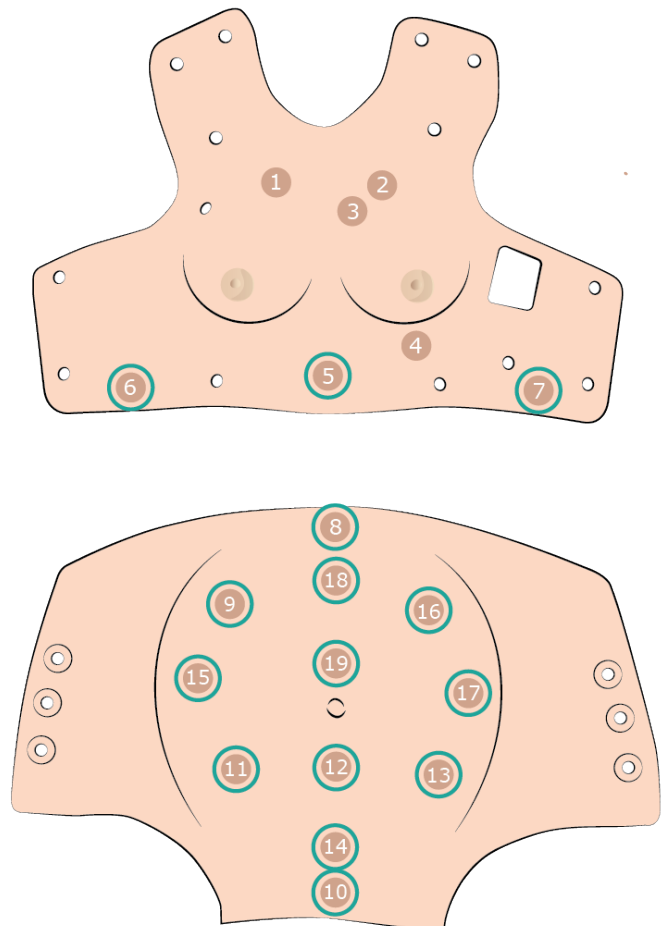
The Late-stage pregnancy bundle contains a healthy patient case in addition to the 10 cases included. The healthy patient case allows participants to see normal anatomy and pathology at each tag location.

Target group(s): Healthcare providers that participate in the care of pregnant patients and senior medical students.

Use: The healthy patient case checklist outlines the findings for each ultrasound window available for this case. Have the participant scan each location and verbalize their findings and confirm these with the checklist. For a comprehensive, expert-narrated summary of each ultrasound window finding, select the *Findings* tab located in the right menu. The locations highlighted in blue are the sites where ultrasound images can be seen.

SimMom Late-Stage Healthy Patient Active Tags:

1. Right Chest
2. Left Chest
3. Parasternal
4. Apical
5. Subcostal
6. Right Upper Quadrant
7. Left Upper Quadrant
8. Proximal IVC
9. Parauterine Right Upper Quadrant
10. Suprapubic
11. Parauterine Left Upper Quadrant
12. Infraumbilical
13. Parauterine Left Lower Quadrant
14. Lower Uterus
15. Parauterine Right Mid Quadrant
16. Parauterine Left Upper Quadrant
17. Parauterine Left Mid Quadrant
18. Upper Uterus
19. Supraumbilical



SimMom Late-Stage Pregnancy Healthy Patient Case Ultrasound Findings:

Ultrasound Window	Findings	Correct Interpretation Yes/No
RUQ	No free fluid in hepatorenal space (Morison's pouch); No hepatobiliary pathology noted; Normal right kidney	
Suprapubic	Fetal cranium visualized; Cephalic presentation	
LUQ	No free fluid in splenorenal space; Normal left kidney	
Subcostal	Normal cardiac function; No pericardial effusion; No right-heart strain	
Proximal IVC	IVC diameter less than or equal to 2.1 cm; Respirophasic collapse greater than 50%; Right atrial pressure 0 to 5 mmHg; Important: limited data with regard to how IVC size and respirophasic changes are affected by uterine compression in second- and third-trimester pregnant patients	
Lower Uterus	BPD and HC measurements at level of fetal brain showing cavum septi pellucidi, third ventricle, and thalami; BPD measures 8.43 cm with a 34w0d gestational age; HC measures 29.35 cm with a 32w3d gestational age	
Infraumbilical	AC measurement at level of fetal stomach, spine, fetal ribs, and intrahepatic segment of umbilical vein at portal sinus; AC measures 32.34 cm with a 36w2d gestational age; Normal four-chamber view of fetal heart	
Supraumbilical	FL measurement from cartilaginous greater trochanteric and lateral condylar junctions with ossified femur; FL measures 6.59 cm with a 34w0d gestational age	
Upper Uterus	Placental attachment at anterior uterine fundus; MVP measures 6.7 cm	
Para Ut RLQ	Limited view due to bowel gas artifact	
Para Ut RMQ	Limited view due to bowel gas artifact	
Para Ut RUQ	Limited view due to bowel gas artifact	
Para Ut LUQ	Limited view due to bowel gas artifact	
Para Ut LMQ	Limited view due to bowel gas artifact	
Para Ut LLQ	Limited view due to bowel gas artifact	